

Abstract Type : Poster

Presentation No. : PGN 021

Rapidly progressive glomerulonephritis and small bowel ulcer bleeding with histologic confirmation in Microscopic polyangiitis

Woo Youn Eom, Inwhee Park, HyoJin Yun, JongCheol Jeong, Gyu-Tae Shin, Heungsoo Kim
Department of Internal Medicine-Nephrology, Ajou University Hospital, Korea, Republic of

Case Study: Microscopic polyangiitis (MPA) is an uncommon systemic small vessel vasculitis. Its characteristic histology shows a necrotizing small vessel vasculitis with little or absent immune deposits (pauci-immune vasculitis). The two organs most typically involved and often defining prognosis are the kidneys and the lungs. MPA may concomitantly or sequentially involve other organs such as the nervous system, the skin, the musculoskeletal system, but also the heart, the eye and the intestines. The most frequent GI symptoms in MPA is abdominal pain of an ischemic nature. However small bowel ulcer bleeding is rare. Furthermore, small bowel histological confirmation of vasculitis is extremely rare. Here, we report the case of MPA with massive hematochezia complicated with vasculitis-associated small bowel ulcer bleeding with histological confirmation of vasculitis, rapidly progressive glomerulonephritis (RPGN), and hemoptysis and pneumonia with known bronchiectasis with history of old pulmonary tuberculosis. The patient was treated using low dose prednisolone and cyclophosphamide. Unfortunately, the patient remains hemodialysis dependent, however extra renal involvement was recovered. At a follow-up visit 3 months after presentation, he reported no recurrence, and he is receiving renal-replacement therapy

figure 1 : Light microscopy kidney biopsy findings (H&E stain)

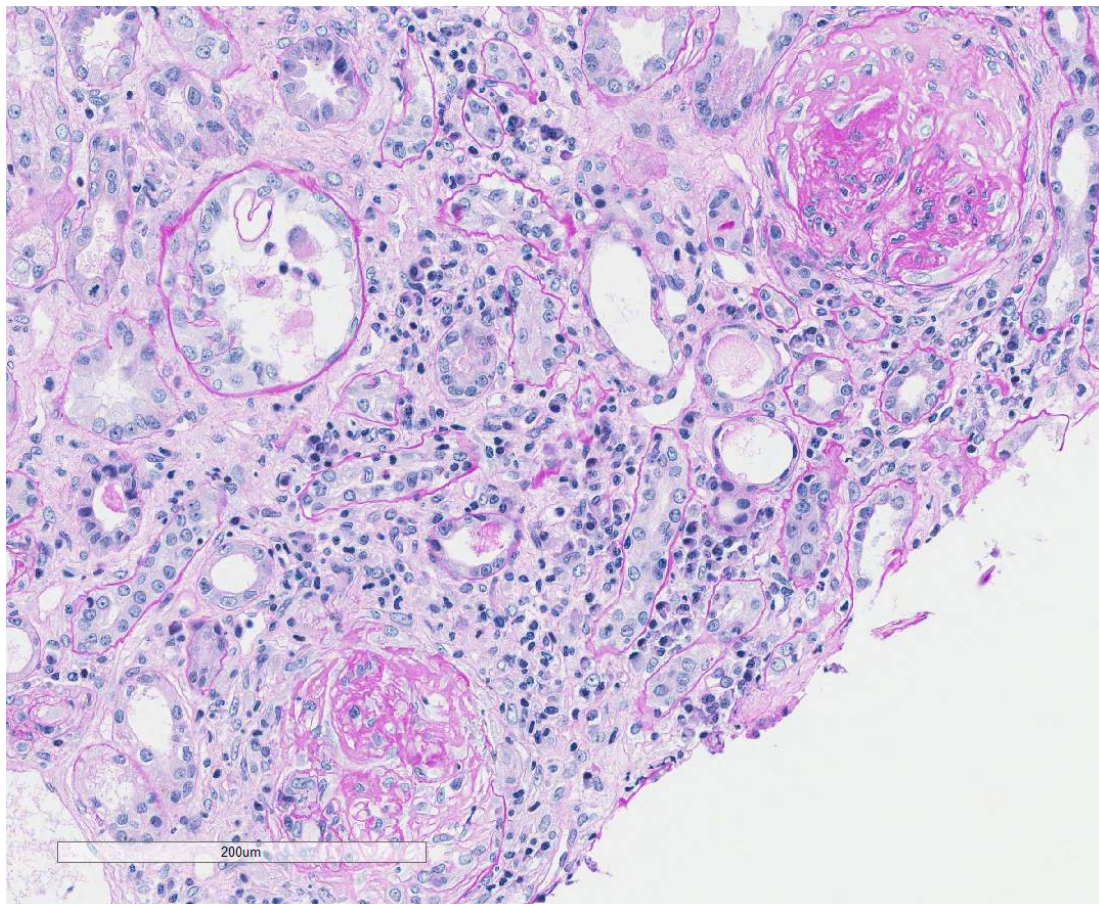


figure 2 : small bowel biopsy findings

